

# Evaluation of the Effect of *Premna Pubescence* Extract against DMBA-Induced Breast Cancer in Female

Martina Restuati\*, Ahmad Shafwan S. Pulungan, Nanda Pratiwi, Trifena Pauline Sirait

Department of Biology, Universitas Negeri Medan, Jl. Willem Iskandar Psr. V, Medan Estate, Medan, Indonesia, 20221

\*Correspondence author: [trestuati@gmail.com](mailto:trestuati@gmail.com)

Article History:

Submitted: 09.01.2020

Revised: 15.02.2020

Accepted: 13.03.2020

## ABSTRACT

Notably, the use of *premna pubescence* has been rooted in Sumatra- Malay philosophy. Besides, consuming the substance has been noted as having an extensive history concerning the supreme curative value and with the accuracy of treating a specific type of sickness that distracts the human bodies. In the context, *premna pubescence* extract has been noted as being responsible for its curative effects as well as bringing some potential regarding the treatment of cancer. There is a current study concerning the effects of *premna pubescence* extract of leaves on the pathological modification associated with breast cancer in feminine rats. Thus, the research needs to investigate the effectiveness of this dosage against cancer. In the study, the rats are given a single dose of DMBA using a gastric tube where they receive three times a week for four weeks. According to the study, the ethanol extract of the dose leaves reserved the pathological modifications in mammary nerves of the female rats persuaded by the DMBA handling. The results of the study show that the ethanol extract of

the dose had an outcome on the constraining ductal epithelial cell explosion as well as ductal length. Besides, this dosage leaves the ethanol excerpt, which is known as the most operative to hinder pathological modification and measures 450 mg/kg. Also, the results show that the dose has a protective consequence against the cancer of the mammary glands. Hence, the antioxidant chattels of the pubescence leave abstract is facilitated by their actions as well as studying other fundamental mechanisms.

**Keywords:** breast cancer, *Premna pubescens*, DMBA, histopathology.

## Correspondance:

Martina Restuati  
Department of Biology, Universitas Negeri Medan, Jl. Willem Iskandar Psr. V, Medan Estate, Medan, Indonesia, 20221

E-mail: [trestuati@gmail.com](mailto:trestuati@gmail.com)

DOI: [10.5530/srp.2020.3.50](https://doi.org/10.5530/srp.2020.3.50)

@Advanced Scientific Research. All rights reserved

## INTRODUCTION

Cancer is one of the most tremendously imposing asset health loads in the world today (Boldt et al., 2019). Besides, it is rated in the second position in wheel source of death, where the heart disorders are the first. In the context, the cancer of the mammary glands is one among the most mutual poisonous that are affecting females in the world today, and the life period approximation is around ten percent. Taking a country like Indonesia, breast cancer is noted as being the most shared among women. In 2016, about one hundred thousand cancer patients were screened in Indonesia, and women represented thirteen point four (13.4) percent of the patients tested. Notably, women have identified breast cancer are at a more significant danger of suffering metastases in their whole life period. In addition, breast cancer is genetically as well as histopathological assorted (Feng et al., 2018).

In the context, Indonesia, particularly Sumatra Island, is well known for having wealth in historical information concerning the curative use of spices as well as herbs. One of the most noted is the ancient orientation concerning the extraordinary use of *premna pubescence*. According to the old texts, *premna pubescence* is used to treat diarrhea as well as other stomach problems (Boldt et al., 2019). Besides, these leaves have an extensive history concerning the unique curative value with the adaptability to treat an inclusive range of diseases, which include; asthma, headaches, colds, diabetes as well as gastrointestinal problems, among others. It is only in this century that the exploration of this kind of leaves that has continued being useful in curatively. According to the reports, these leaves have been used to treat various infections, cancer as well as hypertension. In addition, the minor metabolite of these leaves is believed to be accountable for overwhelming the propagation of the growth cells comprising the breast.

## MATERIAL AND METHODS

## Chemicals and Experimental Animals

The research has been created at the biology laboratory of Medan State University between March and October 2018. In the context, the elements for histopathological inspection study were of the highest concentration available and were purchased in Sigma Aldrich chemical. Besides, the fifty grown-up feminine rats that were bought from the Medan State University had to be maintained on the needed standard laboratory nutrition and water. Also, the animals were divided into five groups and each group had ten members after an acclimation time of a week. Additionally, the animals were housed separately in filter-top cages with polycarbonate and maintained at a temperature of around 23°C, which was taken conducive for the study. Besides, the cages had a twelve hours' light/dark cycle and were free from any spring of chemical contagion.

## The Experimental Design

In the context, the fifty female rats bought from the Medan State University animal house were distributed in the two groups equally. In the research, the first group comprised of the untreated animals and was controlled. Besides, the second group had DMBA treated animals. For the treated animals, they had been treated using a single dosage of DMBA through a gastric tube to persuade breast cancer. In addition, the animals in the two groups were further separated into various sub-groups. The first sub-group comprised of the DMBA-treated animals, which were left for four weeks without extra treatment. Perhaps, there were two to five subgroups, that consist of DMBA-treated animals, which were complemented vocally for four weeks, three times per week. Furthermore, at the end of the experimental time, the animals were forfeited after the four weeks of DMBA treatment. The breast tissues were kept in a formalin solution, which was ten percent till the conclusion of the thrash, as well as the begging of analysis concerning the histological checkup for all the treated animals (Feng et al., 2018).

### The Plant Extracts

In the study, the supercritical liquid abstraction of ethanol extract of *prema pubescence* leaves was extracted. This was done carefully using the softening extraction arrangement with negligible alterations (Feng et al., 2018). The leaves seeds were cleaned briefly and dried using an oven at 40°C till a persistent weight was attained. In addition, a hundred grams of the leaves were crushed into powder for about a minute using an electrical grinder before the abstraction was initiated. In the context, the extraction was done using the ethanol, which was supplied to the abstraction unit. Hence, a hundred grams of the extract powder was placed in the abstraction vessels. After this, the abstraction process was performed by the use of ethanol abounding to an abstracting unit. Besides, the unit was fortified with an extractor vessel as well as three hurricanes separators. Also, the extraction vessel was strongly sealed, and the desired temperature of 25°C was maintained.

### RESULTS

The Histopathological Checkup and Statistical Analysis  
The tissue samples from the breast of female rats of various experimental clusters were put in neutral cushioned formalin of ten percent and administered by a conventional method, entrenched in paraffin and stressed by hematoxylin. In addition, all the results were articulated as mean with a standard of error. In the context, the data was examined using a one-way analysis of variance (ANOVA) and SPSS. Then the activity was followed by Scheffe test for comparison of the significance between the groups. Notably, the differences in the results were considered to be significant when  $p > 0.05$ . According to the results obtained, as shown in the figure below, the DMBA-treated rats displayed expressively higher standards of the body weight compared to the other group of the control rats. That is ( $t=7\%$  and  $p < 0.001$ ). However, it was also noted that the treatment of the female rats using this type of leaves led to a decrease of the body weight ranks, encouraged by DMBA.

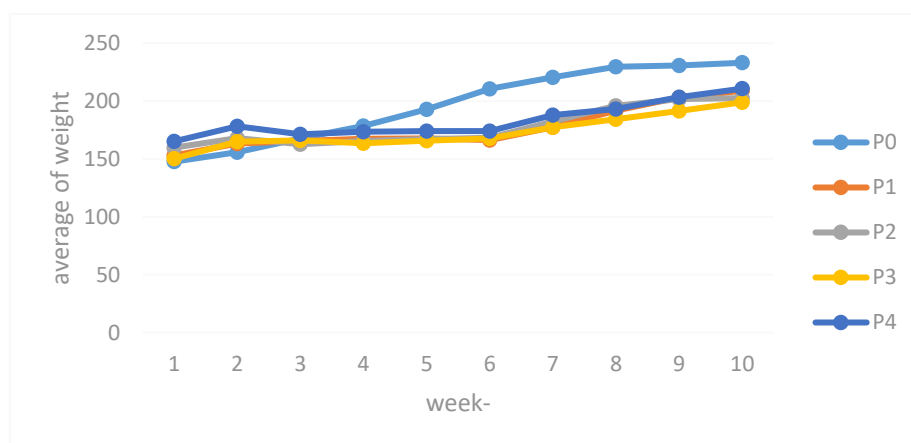


Figure 1: Influence of ethanol abstract of pubescence leaves on the bodyweight of the rat (Patel, 2018).

In the context, the comparison of the two groups (control and the DMBA treated) breasts will be displayed in the next figure. The analysis was done on the breast tissue from the control rats group, and the group did not have any stomach issues. Besides, the mammary glands of the control group displayed standard lobular style having diverged ducts as

well as the normal distribution of fat tissues. Hence, the control group tissue at the end of four weeks was s unaffected mammary weight comparative to the earlier period points. Nevertheless, the treatment using the DMBA alone encouraged a growth in the breast tissues of the selected animals during the four weeks of treatment.

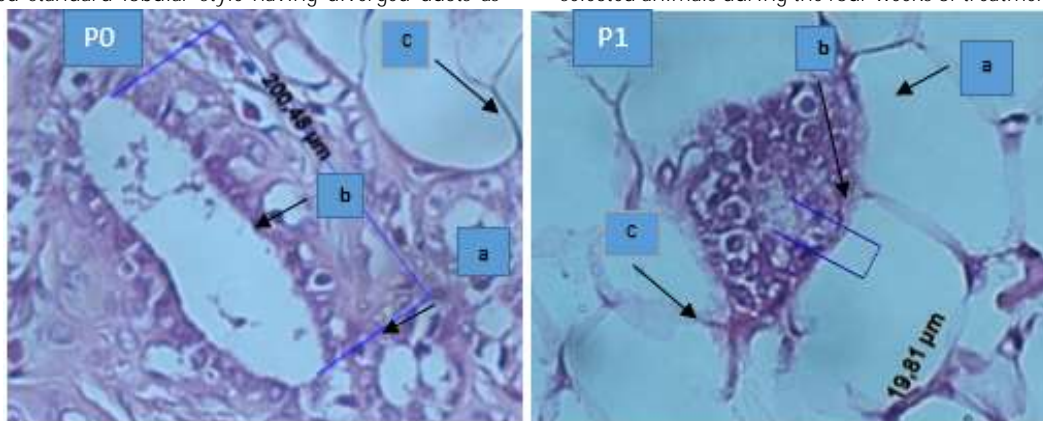


Figure 2: Breast tissue of the selected female rats. Relationship of the selected members in both groups showing the difference between the treated and control group (Boldt et al., 2019).

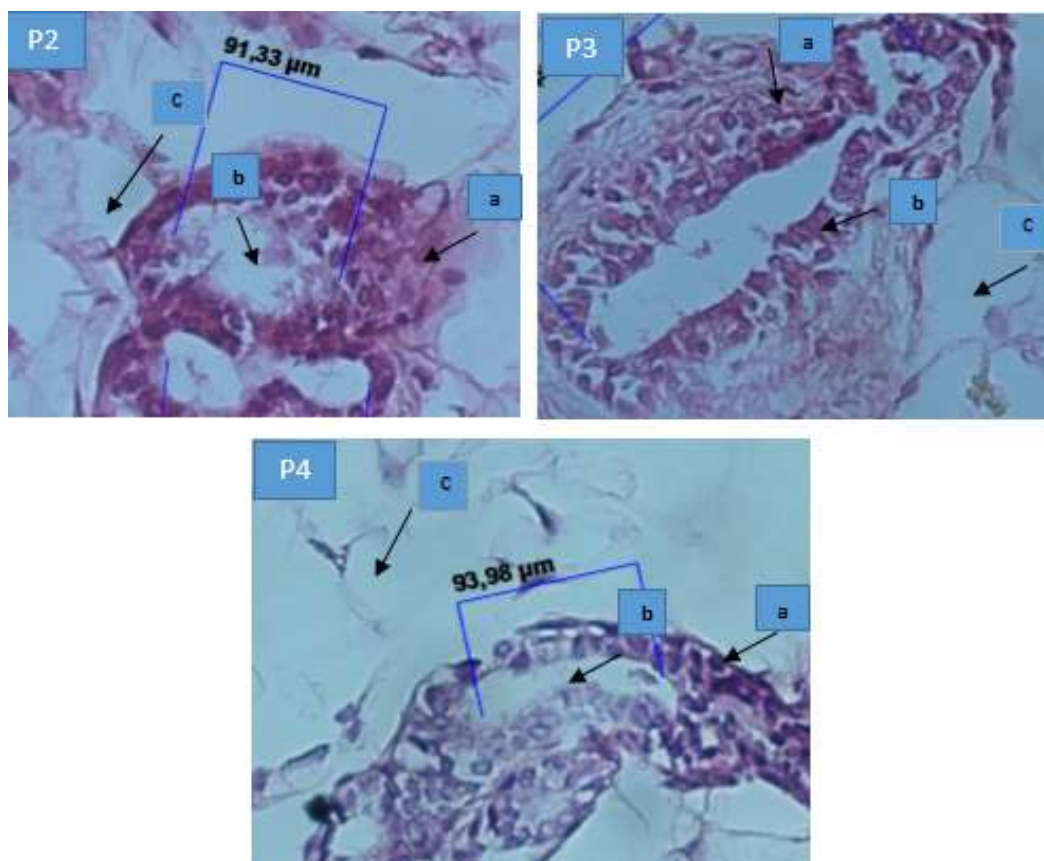


Figure 3: Representation of the mammary tissue of the morphology in regard to the treated as well as the control animals in the selected rats (Boldt et al., 2019).

In the context, the study in its analysis demonstrated a different morphology, which had a compact pattern irrespective of the presence or absence of the comedo necrosis predetermination. On the other hand, the cystic-papillary, as well as the cribriform, are present in the context; the breasts of the control rats group demonstrate a typical lobular design, which comprises of diverged ducts as well as a normal distribution of the stout tissues. Besides, the control mammary tissues at the end of the four weeks were not changed compared to the earlier recorded period points. In addition, there was a similar observation that was prepared concerning the ethanol abstract of these leaves for the treated group of rats. According to the study, the abstract of these leaves stirred mammary glands to demonstrate increase propagation in regard to enlarged ducts that contained inspissated excretions. Also, there was an increase in the distribution and development of the incurable lobular elements. Thus, I conveyed by the firmness of and growth into the neighboring stout tissue. In the analysis of the study, as shown by the figure above, it is discovered that when the cystic papillary, as well as the cribriform patterns, are existing, the assault was restricted to the focus of micro-invasion. Actually, the micro-invasive concentration was detected and described with the help of

breaking down the basal tissue of the propagation of classic small glands (Rojas & Stuckey, 2016). Hence, these glands assaulted the neighboring stroma enclosed by a prominent desmoplastic response.

On the other hand, there is a similar observation concerning the control tissues that were made in regard to the ethanol extract of pubescence leaves to the treatment of the selected rats. The control and ethanol extract of these leaves stirred the mammary gland showed increased propagation with the enlarged ducts that contained insisted excretions as well as improved propagation and development of incurable lobular elements, which are conveyed by compression of and development into the neighboring fat tissue (Rojas & Stuckey, 2016).

#### Mammal Ductal Epithelial Cells of the DMBA Treated Rat Members

The results concerning the amount of mammary epithelial cell sheets of the rat members' tissues of the treated group will be displayed in the figure below. In the context, the results publicized that the amount of cell sheets has lessened in the group that was given the extract. On the other hand, in the positive control, the ductal lumen cell sheet has been noted increasing.

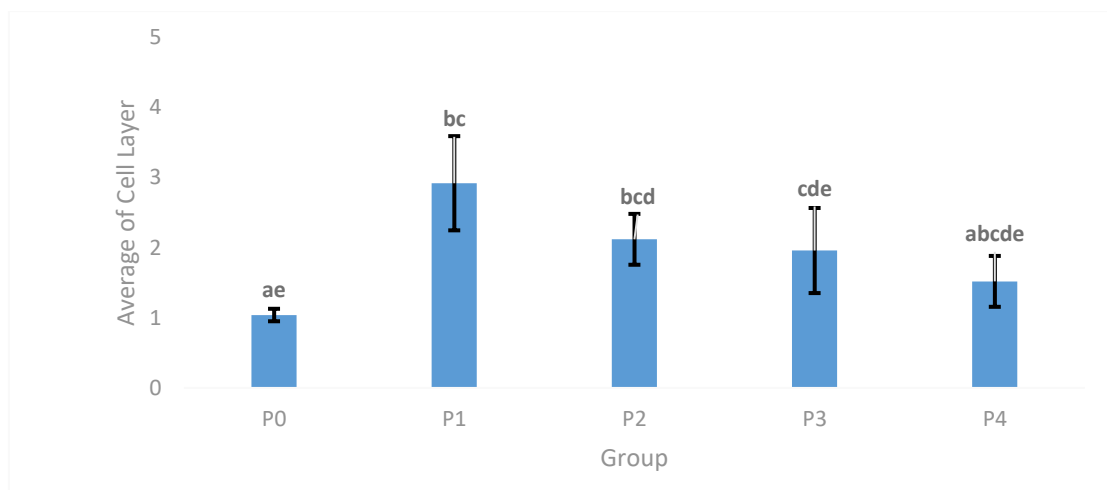


Figure 4: the effect of the ethanol extract on the number of cell sheets of the DMBA treated members (Everitt, 2016).

In the figure above, the means which are presenting altered lettering, that is (a-e) between the columns are seen differing expressively, that is, ( $p < 0.05$ ) and ( $ap < 0.05$ ), when compared to the members in the control group. On the other hand, the pb was  $< 0.05$  matched with the treated group, and cp was  $< 0.05$  when compared to the treated group + the ethanol abstract of p. besides, the data were analyzed using the ANOVA, and the Scheffe test for comparison purposes followed the results.

#### Ductal Diameter in the Gland of the Treated Rats

According to the results, it can be seen that the duct diameter of the glands of the treated rats varies as a result of the treatment that is intensively provided to these rats. In the context, the smaller the diameter specifies that the histology varies in the stomach duct. The figure below has been used to show the diameter of the rats against their treatment.

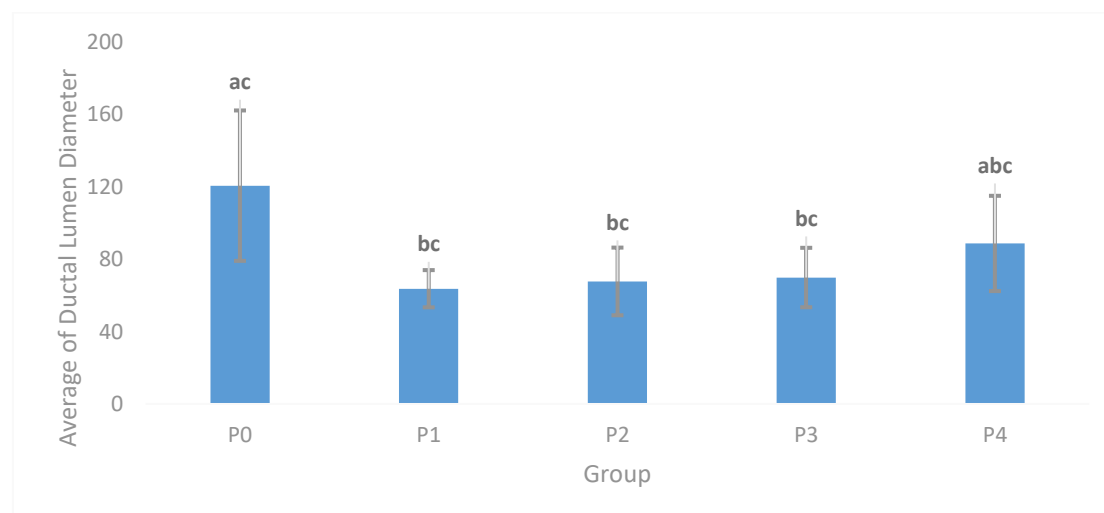


Figure 5: The effect of the abstract of the leaves to the ductal diameter of the DMBA treated rats (Wen et al., 2017)

In the figure above, it can be noted that the means (showed by different letters a, b, c) in the columns varied expressively. That is for the compared control group, at  $p < 0.05$  and  $ap < 0.05$ . For the compared treated group,  $bp < 0.05$  and  $cp < 0.05$ , that is, in comparison to DMBA + ethanol extract from the pubescence leaves in the group. The data was evaluated using the ANOVA, and then scheffe test was done (Diningrat & Marwani, 2018).

## DISCUSSION

As used in the context, *premna pubescence* is a persistent plant. Besides, the plant contains leaves that retain

enormous curative assessment (Everitt, 2016). In the setting, the leaves' ethanol abstract comprehends alkaloid, tannin, flavonoid, as well as various phytochemicals, which aid in treating a diversity of circumstances. For instance, it can be used to treat sicknesses such as; hypertension, gastrointestinal disorders, dizziness, diabetes, as well as fever. Also, there is a variety of plant abstracts or arrangements that are accessible today concerning treating any figure of diseases distressing the human body. Therefore, like the most curative plant, the method of pubescence diverges with the topographical dispersal, the period of yield as well as agronomic observes. In addition, its health-ornamental latent has been accredited to the

active elements that mainly exist in its static and ethanol abstract (Rojas & Stuckey, 2016).

Therefore, the chief objective of this study was to appraise the effectiveness of ethanol abstract of these particular leaves on overwhelming the breast cancer particular variations of human mammary carcinoma tumor capacity. In the study, no data are deliberating the defensive role of ethanol abstract of these leaves in the reticence of the development of breast cancer prompted by DMBA treatment in female rats.

In the context, the histopathological checkup of the present study discovered that DMBA-treated rats complemented with the ethanol abstract of pubescence leave displayed incentive in the mammary gland as well as dominance in the advancement of the mammary tumor cell propagation (Wen et al., 2017). According to the findings of the study, there is an indication of the restriction in the neoplastic variations throughout the consecutive phases of the carcinogenesis concerning the DMBA-treated male Syrian hamsters complemented by the *Nigella sativa*. Also, there was a description in regard to the use of flavors, leafy tubers as well as condiments which have assorted curative chattels. In the study, the Products of about twenty flavors or leafy tubers, such as the black cumin, were selected for anti-carcinogenic action. In that action, Ethanol extract of pubescence leaves measures have also established the importance of in vitro as well as in vivo antineoplastic movement Tumor developments (Everitt, 2016). As a result, the DMBA treatment is virtually always conveyed by a rise in the sum of mammary gland duct cell sheets.

On the other hand, the anti-carcinogenic efficiency of ethanol extract of these leaves is accredited to numerous reasons, for instance, the enrichment of the anti-oxidation movement. The anti-carcinogenic effectiveness of these leaves was established with the growth of the quantity of mammary gland duct cell sheets movement in the research. According to the findings, the results of the present study found that ethanol extract of pubescence leaves on the ductal length in the gland of the DMBA treated rats were capable of decrease the improvement of mammary tumors in feminine rats encouraged by the DMBA dosage as well as decline (Wen et al., 2017).

The remediation appliance of ethanol abstract of the pubescence leaves in contradiction of breast cancer was accredited to their antioxidant movement. Besides, the protuberant antioxidant movement of these leaves was comprehensively acknowledged in dissimilar tentative circumstances, for instance, hepatic-carcinogenesis. Also, it has been shown that this ethanol extract prevents non-enzymatic fat peroxidation in liposomes. With the help of GCMS chromatography, it can be seen that composites sequestered from pubescence, for instance, the carvacrol, t-anethole, thymoquinone, as well as 4-terpineol have considerable unrestricted fundamental searching possessions (Diningrat & Marwani, 2018).

In addition, the compounds in the study were established in a sequence of other in vitro assessments to ensure antioxidant movement, though there are no pro-oxidant possessions. Hence, the antioxidant accomplishment of these specific leaves can be used to explain its claimed

effectiveness in common treatment (Everitt, 2016). Additionally, this antioxidant possession would describe its accomplishment alongside hepatotoxicity, cirrhosis, liver fibrosis, as well as hepatic destruction persuaded by the *Schistosoma* contagion.

## CONCLUSION

In conclusion, as seen in the context, the results of this study show clearly that the ethanol abstract of pubescence leaves immediate no destructive effects to the feminine rat breast nerves. Besides, this abstract employ a defensive possession alongside the breast carcinogens. However, the antioxidant stuff is arbitrated by their arrangements, hence, exploring other fundamental devices necessitates more studies (Diningrat & Marwani, 2018).

Besides, the study has also recognized cancer being one of the most dangerous notables in strength health problems in the world today. Also, this disease is second concerning death cause; the first known death cause is heart disorders. In relation to this, the study has identified breast cancer is one of the most mutually deadly infections among women today. From the survey, the DMBA treated animals displayed expressively higher values of their body weight when compared to the animals in the control group. However, the treated animals decreased their body heaviness ranks. The cause was the use of DMBA in treatment (Rojas & Stuckey, 2016).

After the observation, the study states that the mammary tissue of the rats in the control group did not have any stomach issues. Concerning the rats in the control group, their mammary glands showed a standard design which had branched vessels as well as a healthy distributed fat tissue. Besides, their fabric was unchanged after the observation period (Diningrat & Marwani, 2018). Similarly, the same observations were made concerning the ethanol-treated rats, and as seen earlier, the ethanol extract is working as a stimulant towards mammary glands showing an increased propagation.

In the context, the leaves of a pubescence plant are very important in terms of curative purposes. Ethanol extractions of this plant contain some significant chemicals which can cure diseases such as; diabetes, hypertension, fever, dizziness as well as disorders related to gastro intestine conditions. Currently, there exist plants' extractions that are being used to treat various diseases (Diningrat & Marwani, 2018). According to this study, the effectiveness of the extract from this plant leaves towards overwhelming the mammary gland cancer in women has been noted changing the women mammary glands carcinoma capacity.

However, regarding the knowledge of the authors of this study, there were no available figures or statistics that would help in understanding the defensive part of the ethanol extract of pubescence leaves in hindering the development of the mammary gland cancer that would be persuaded by the DMBA treatment to female rats (Rojas & Stuckey, 2016). Also, there is a similarity between the results of a current study and the findings of this study. Both are demonstrating the restrictions related to the neoplastic alterations mainly

during the consecutive phases of the carcinogenesis on the DMBA treated males from Syrian.

Lastly, in the study, it has been noted that the value of the ethanol extract of pubescence leaves alongside the mammary gland cancer was accredited to the female antioxidant actions. Hence, the antioxidant action of this extract was broadly acknowledged. Besides, this extract from the pubescence leaves hinder the non- enzymatic fat peroxidation mostly in liposomes (Rojas & Stuckey, 2016).

#### ACKNOWLEDGMENTS

The research was well supported by the higher education department in the Republic of Indonesia as well as a grant which was from the ministry of technology and study of the same country. Besides, the authors would like to take this opportunity to appreciate everyone who assisted in any way during the study. Moreover, we would also like to appreciate the deanship of the scientific research for the immeasurable support we received from you, mostly the financial support that enabled the conducive conducting of the study. Lastly, the authors of this research would like to recognize the facilitator who directed them on how to go about it; without you, all this work would not be accomplished.

#### CONFLICT OF INTEREST

The authors of this study have decided to declare no conflict of interest concerning the research.

#### REFERENCES

- Adedoyin, B. A., Muhammed, A. B., Dangoggo, S. M., Rabah, A. B., Sharples, G. P., & Sarker, S. D. (2018). GC-FID and GC-MS analyses, and bioactivity assessment of the essential oil of Cassia Singueana Delile flower. *Reviews of Clinical Pharmacology and Drug Therapy*, 16(2), 2.
- Ali, M. (2017). *Pharmacological and Toxicological Study of Medicinally Important Plant: Drynaria quercifolia (rhizome)* (Doctoral dissertation, East West University).
- Asuzu, P. C. (2019). *In vitro Assessment of Phytoconstituents, Efficacy and Cytotoxicity of Extracts from Medicinal Plants on Prostate Cancer C4-2 Cells* (Doctoral dissertation, Delaware State University).
- Boldt, P., Knechtle, B., Nikolaidis, P., Lechleitner, C., Wirnitzer, G., Leitzmann, C., & Wirnitzer, K. (2019). Sex differences in the health status of endurance runners: Results from the NURMI study (step 2). *The Journal of Strength & Conditioning Research*, 33(7), 1929-1940.
- Debonis, D. L. (2020). Prevention of breast cancer in patients with siliconomas. In G.E. Schenone, *Injection-induced breast siliconomas* (pp. 185-194). Springer.
- Diningrat, D. S., & Marwani, E. (2018). De novo transcriptome profiling of buasbuas (*Premna pubescens*. Blume). *Biotechnology*, 17(2), 75-85.
- Everitt, B. S. (2016). Let's talk about cancer. In B.S.S. Everitt, *Health and lifestyle: Separating the truth from the myth with statistics* (pp. 67-96). Copernicus.
- Feng, Y., Spezia, M., Huang, S., Yuan, C., Zeng, Z., Zhang, L., ... & Liu, B. (2018). Breast cancer development and progression: Risk factors, cancer stem cells, signaling pathways, genomics, and molecular pathogenesis. *Genes & Diseases*, 5(2), 77-106.
- Patel, S. (2018). Breast cancer: Lesser-known facets and hypotheses. *Biomedicine & Pharmacotherapy*, 98, 499-506.
- Restuati, M., Hidayat, U., Pulungan, A. S. S., Pratiwi, N., & Diningrat, D. S. (2016). Antibacterial Activity of Buasbuas (*Premna pubescens* Blume) Leaf Extracts against *Bacillus cereus* and *Escherichia coli*. *Journal of Plant Sciences*, 11(4), 81-85.
- Restuati, M., Pratiwi, N., & Widiyastuti, G. (2017, August). Effect of leaf extract buasbuas (*Premna pubescens* Blume) for against of bacteria growth *Staphylococcus aureus* and *Salmonella* sp in vitro. In *AIP Conference Proceedings* (Vol. 1868, No. 1, p. 090007). AIP Publishing LLC.
- Rojas, K., & Stuckey, A. (2016). Breast cancer epidemiology and risk factors. *Clinical Obstetrics and Gynecology*, 59(4), 651-672.
- Tucker, D. K., Foley, J. F., Hayes-Bouknight, S. A., & Fenton, S. E. (2016). Preparation of high-quality hematoxylin and eosin-stained sections from rodent mammary gland whole mounts for histopathologic review. *Toxicologic Pathology*, 44(7), 1059-1064.
- Wen, X., Hempel, J., Schweiggert, R. M., Ni, Y., & Carle, R. (2017). Carotenoids and carotenoid esters of red and yellow physalis (*Physalis alkekengi* L. and *P. pubescens* L.) fruits and calyces. *Journal of Agricultural and Food Chemistry*, 65(30), 6140-6151.
- Firdous, N., Nasa, P., Bansal, A., Juneja, D., Kanwar, M.S., Bera, M.L. Comparison of non-invasive diagnostic tests to multi-detector CT pulmonary angiography for the diagnosis of pulmonary embolism (2013) *Journal of Cardiovascular Disease Research*, 4 (1), pp. 40-43. DOI: 10.1016/j.jcdr.2013.02.004